Reprinted with permission from
ECHOCARDIOGRAPHY, Volume 18, No. 3, April 2001
Copyright ©2001 by Futura Publishing Company, Inc., Armonk, NY 10504-0418

Noninvasive Transcutaneous Low Frequency Ultrasound Enhances Thrombolysis in Peripheral and Coronary Arteries

Robert J. Siegel, M.D., Shaul Atar, M.D., Michael C. Fishbein, M.D., Andrea V. Brasch, M.D., Thomas M. Peterson, M.B.A., Tomoo Nagai, M.D., Dharmendra Pal, M.S., Toshihiko Nishioka, M.D., Jang-Seong Chae, M.D., Ph.D., Yochai Birnbaum, M.D., Claudio Zanelli, Ph.D., and Huai Luo, M.D.

Division of Cardiology, Department of Medicine, Cedars-Sinai Medical Center, 8700 Beverly Boulevard, Los Angeles, California

Previous studies have shown that external ultrasound with low frequencies and high intensities can enhance thrombolytic drug-induced clot dissolution during in vitro experiments. In this series of studies, we evaluated the efficacy of peripheral and coronary thrombolysis in vivo in animals by using noninvasive transcutaneous ultrasound combined with thrombolytic drugs (streptokinase and tPA) and/or microbubbles agents (dodecafluoropentane [DDFP] and perfluorocarbon-exposed sonicated dextrose albumin [PESDA]). Thrombotic occlusions were induced in 74 rabbit iliofemoral arteries and 24 canine left anterior descending (LAD) coronary arteries in this in vivo study. By using the combination of transcutaneous ultrasound and streptokinase, the angiographic patency rate in rabbit iliofemoral arteries was higher (56%–100%) than with ultrasound (6%; $P \leq 0.0036$) and streptokinase alone (6%; $P \leq 0.0012$). Also, with transcutaneous ultrasound and microbubbles, the angiographic patency rates were 76%–100% as compared with ultrasound alone (0%, $P \leq 0.0003$) or microbubbles alone (9%, $P \leq 0.0001$). In the canine study of acute myocardial infarction, thrombolysis in myocardial infarction (TIMI) grade flow at 90 minutes in the tPA alone group was 0.92 ± 1.4 as compared with 2.42 ± 1.9 in the tPA plus transthoracic ultrasound group ($P = 0.006$). There was much improved reperfusion with tPA plus ultrasound as compared with tPA alone. In vivo animal studies demonstrate that noninvasive transcutaneous ultrasound can greatly enhance the effect of clot dissolution with thrombolytic drugs and/or microbubbles, and has the potential for clinical application as an adjunctive method to improve arterial thrombolysis. (ECHOCARDIOGRAPHY, Volume 18, April 2001)

thrombolysis, ultrasonics, fibrinolysis

For the past decade in our laboratory we have been studying the use of noninvasive ultrasound for thrombus dissolution. Initial in vitro studies showed that for a fixed power output, mechanical thrombolysis (no adjunctive drug or agent) was substantially more efficient at lower frequencies of 25–50 kHz as compared with ultrasound at higher frequencies.[1] While evaluating the use of ultrasound with thrombolytic drugs in vitro, we found that there was greater augmentation of thrombolysis with lower frequencies (i.e., kHz vs MHZ) and also with high power intensities.[2] The augmentation of thrombolysis by ultrasound occurs with streptokinase, urokinase, and tPA.[2,3] Moreover, others and us have found enhancement of ultrasound clot dissolution to occur with perfluorocarbon microbubbles[4,5] as well as with other microparticles.[6] In this paper we describe in vivo animal experiments performed in our laboratory to assess the utility, applicability, and safety of noninvasive transcutaneous ultrasound for augmentation of clot lysis with thrombolytic drugs as well as with perfluorocarbon microbubbles for peripheral and coronary thrombolysis.

This study was supported in part by the Piansky Family Anatomic Research Fund.

Address for correspondence and reprint requests: Robert J. Siegel, M.D. , Division of Cardiology, Room # 5335, Cedars-Sinai Medical Center, 8700 Beverly Boulevard, Los Angeles, CA 90048 . Fax: 310-423-0318; E-mail: siegel@cshs.org

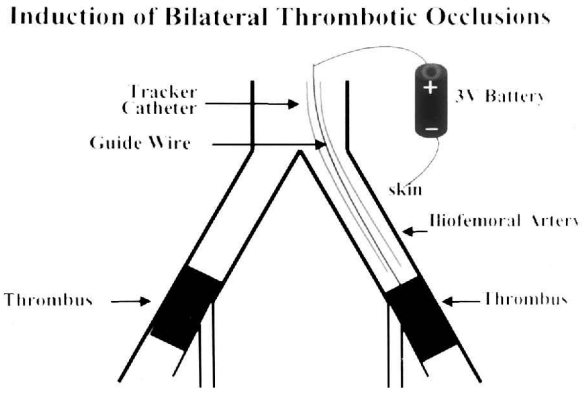

Figure 1. *Schematic showing method for bilateral electrical induction of occlusion in thrombotic rabbit iliofemoral arteries.*

Methods

In these animal studies, the American Physiological Society Guidelines for Animal Research were followed, which conform to the position of the American Heart Association on Research Animal Use.

Peripheral Arterial Applications of Ultrasound in Thrombotically Occluded Rabbit Iliofemoral Arteries

Thrombus Preparation—Induction of Bilateral Iliofemoral Thrombotic Occlusions. The method used to induce arterial thrombus was described previously and is illustrated in Figure 1.[7] A 0.014 inch coronary guidewire is advanced into the proximal part of the iliofemoral artery 1 cm beyond the tip of a Tracker catheter (Boston Scientific, Cork, Ireland). The positive electrode of a 3-volt battery is connected to the guidewire and the negative electrode to the rabbit's skin. Occlusion is induced in both iliofemoral arteries in a random order. Thrombotic occlusion of the artery is confirmed by selective angiography.

Application of Transcutaneous Ultrasound. After angiographic documentation of bilateral total occlusions of the iliofemoral arteries, one iliofemoral artery with either the older or younger thrombus is randomized to transcutaneous ultrasound, and the contralateral artery serves as a control. The ultrasound transducer is applied transcutaneously over the area of the thrombotically occluded artery.

Ultrasound in Combination with Streptokinase—Rabbit Protocols 1, 2, and 3

As shown in Table I, three protocols were used with three different low frequency (20–37 kHz) ultrasound devices in combination with streptokinase.[7–9] Rabbits received intravenous streptokinase (25,000 units/kg). While one iliofemoral artery was exposed to transcutaneous ultrasound, the contralateral artery served as control with streptokinase alone. Bilateral iliofemoral angiography was repeated every 15 minutes of treatment for assessment of patency. If the ultrasound-treated artery was still thrombotically occluded, an additional 15-minute ultrasound therapy was repeated (up to a total of 4 periods of 15 minutes). When recanalization occurred, heparin (1000 units) was administered intravenously, and the rabbit was monitored for an additional 60 minutes with serial angiography every 15 minutes to monitor arterial patency. In 14 rabbits, thrombotically occluded iliofemoral arteries were used to assess the effect of ultrasound alone without streptokinase. We assessed the potential for damage after electrical induction as well as after ultrasound treatment. In rabbit protocol 3, serum creatine kinase (CK), lactate dehydrogenase (LDH) levels, red blood cell (RBC) counts, and platelet counts were checked at baseline, after thrombus induction, and after ultrasound to assess for possible tissue damage, he-

TABLE I

Summary of Results from Five Different Protocols Using Transcutaneous Ultrasound in Rabbits

		Ultrasound Frequency & Power	Patency in Combined Ultrasound Group	Vs Patency in Control (No Ultrasound)	Vs Patency in Control (Ultrasound Alone)	Cooling System	Soft Tissue Injury
1	SK	26 kHz, 18 W/cm^2	56% (10/17)	6% (1/17), P = 0.0012	6% (1/14), P = 0.0036	(−)	(yes)
2	SK + DDFP	20 kHz, 1.5 W/cm^2	87% (13/15)	6.7% (1/15), P < 0.05	N/A	9/15(+)	9/15(no)
3	SK	37 kHz, max. 160 W	100% (15/15)	6.7% (1/15), P = 0.001	N/A	(+)	(no)
4	DDFP	20 kHz, 1.5 W/cm^2	76% (13/17)	9% (1/11), P = 0.0001	0% (0/6), P = 0.0001	(−)	(yes)
5	PESDA	37 kHz, max. 160 W	100% (10/10)	0% (0/10), P < 0.0001	0% (0/5), P = 0.0003	(+)	(no)

DDFP = dodecafluoropentane; PESDA = perfluorocarbon-exposed sonicated dextrose albumin.

molysis, and platelet effects related to ultrasound exposure.[9]

Ultrasound in Combination with Perfluorocarbon Microbubbles–Experimental Protocols 4 and 5

Experimental Protocol 4. Dodecafluoropentane (DDFP, 2 ml, initial dose) was injected via Tracker catheter into the iliac artery proximal to the thrombotically occluded site in 11 rabbits (22 iliofemoral arteries).[4] Unilaterally, thrombosed arteries received ultrasound (20 kHz) plus DDFP, whereas the contralateral 11 arteries with ultrasound alone served as control. An additional six thrombotically occluded iliofemoral arteries with intraarterial DDFP alone served as control.

Experimental Protocol 5. Intravenous perfluorocarbon-exposed sonicated dextrose albumin (PESDA, 1 ml) was infused slowly over 5 minutes via ear vein catheter in 10 rabbits (20 iliofemoral arteries).[5] One of the thrombotically occluded arteries received transcutaneous ultrasound (37 kHz), whereas the contralateral 10 arteries served as control with PESDA alone. When recanalization occurred, heparin (1000 units) was administered intravenously, and the rabbit was followed for an additional 60 minutes with repeat bilateral angiography every 15 minutes to assess patency of the arteries. An additional five thrombotically occluded iliofemoral arteries from three rabbits served as a control for ultrasound exposure alone (without PESDA).

Results in Rabbit Peripheral Arteries—Angiographic Findings

Ultrasound and Streptokinase. As shown in Table I, the angiographic patency rate in protocols 1, 2, and 3[6–8] in the iliofemoral arteries treated with the combination of streptokinase and ultrasound was significantly higher than that with either ultrasound or with streptokinase alone.[6–8] The angiogram in Figure 2 shows effective noninvasive recanalization of a rabbit iliofemoral artery using ultrasound and streptokinase. The effects of both ultrasound and streptokinase alone did not differ; in this model, neither one alone was effective for thrombolysis. Conversely, as shown in Figure 3, the combination of ultrasound and streptokinase was highly effective for thrombolysis. Ten of 15 arteries were patent by 30 minutes, and all 15 (100%) had thrombolysis in myocardial infarction (TIMI) 3 flow at 1 hour. There were no angiographic reocclusions in the 30 minute observation period after the initial recanalization. Table II shows that there was no significant change in LDH or CK levels, or in RBC or platelet counts after ultrasound treatment.

Ultrasound and Perfluorocarbon Microbubbles (DDFP and PESDA). In protocol 4, 13/17 (76%, TIMI grade 2–3 flow) iliofemoral arteries were recanalized after the combination of intraarterial DDFP and ultrasound treatment.[4] TIMI grade 3 flow was achieved in 11 (64%) and TIMI grade 2 flow was achieved in 2 (12%), whereas only 1/11 with the DDFP alone had TIMI grade 2 flow and 0/6 with ultrasound alone had any increased arterial patency.

In protocol 5, all 10 arteries treated with intravenous PESDA and ultrasound reopened.[5] As shown in Figure 4, five of 10 arteries recanalized after 30 minutes of ultrasound exposure, and all 10 recanalized after a cumulative time period of 60 minutes. In contrast, none of the contralateral arteries exposed to PESDA without ultrasound recanalized during the same period ($P < 0.0001$); however, three of them reperfused during the 30-minute observation period. None of the five control arteries treated with ultrasound alone without PESDA reperfused ($P < 0.0003$). After thrombus induction, the mean D-dimer level was 5500 ± 3535 ng/ml; after ultrasound plus PESDA therapy resulted in angiographic arterial patency, the mean D-dimer level was 2650 ± 3008 ng/ml; and 1 hour after 1000 units of heparin and monitoring to confirm arterial patency, the mean D-dimer level was 800 ± 410 ng/ml.[5]

Histopathology. Histologic evaluation revealed that rabbit iliofemoral arteries that were patent by angiography also were patent by microscopy with only focal residual mural thrombus, whereas arteries that remained occluded until the end of the angiographic protocol showed occlusive thrombi. Small microscopic areas of focal necrosis were found in the arterial wall in all vessels. The magnitude of vessel injury was the same in the ultrasound-treated arteries as in the control arteries. Figure 5A is an example of a thrombotic occlusion in an iliofemoral artery. Figures 5B and 5C show that the patent vessel has only focal residual mural thrombus (after ultrasound and streptokinase). In protocols 1 and 4, no cooling system was coupled to the ultrasound transducer, and the rabbit dermis as well as subcutaneous soft tissue at the site of ultra-

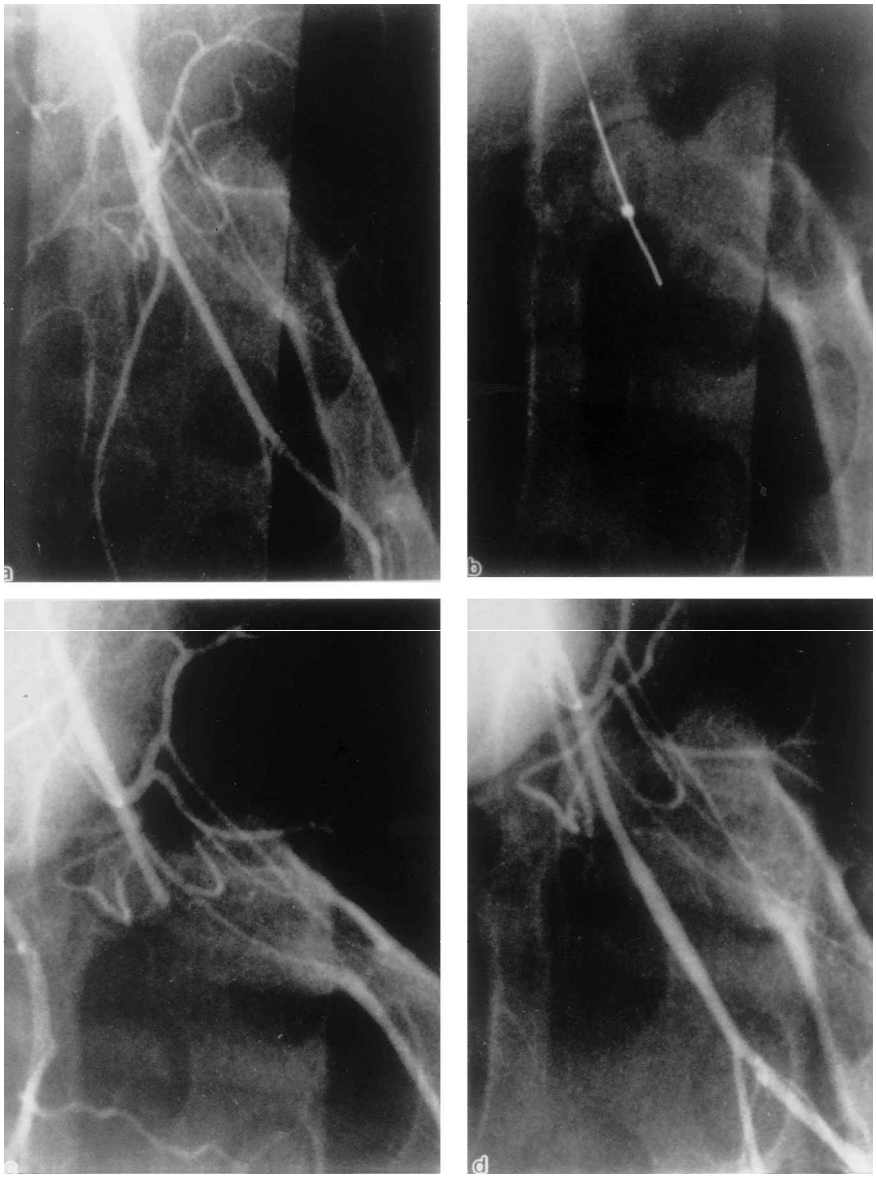

Figure 2. *Angiographic example of left iliofemoral artery treated with transcutaneous ultrasound and streptokinase.* **A.** *Baseline.* **B.** *Guidewire-assisted electrical induction of thrombotic occlusion of the artery.* **C.** *Thrombotic occlusion.* **D.** *Widely patent artery after 30 minutes of treatment.*

sound exposure revealed thermal damage characterized by coagulation of the tissue (necrosis) with focal hemorrhage. After the subsequent development of specialized therapeutic ultrasound transducers (i.e., a cooling system coupled to the ultrasound transducer) as well as other technical improvements in transducer design,[5,8,9] there was no evidence of damage or inflammation to the skin, soft tissues, arteries, or veins that had been exposed to ultrasound.

Canine Studies of Acute Myocardial Infarction—Coronary Thrombotic Occlusions

Thrombus Preparation—Induction of Coronary Thrombotic Occlusion. Thrombotic coronary artery occlusions are induced by electrical injury, as initially described by Salazar[10] and subsequently modified in our laboratory.[11,12] A Tracker catheter with a 0.014 inch (0.36 mm) coronary guidewire is introduced to the midportion of the left anterior descending

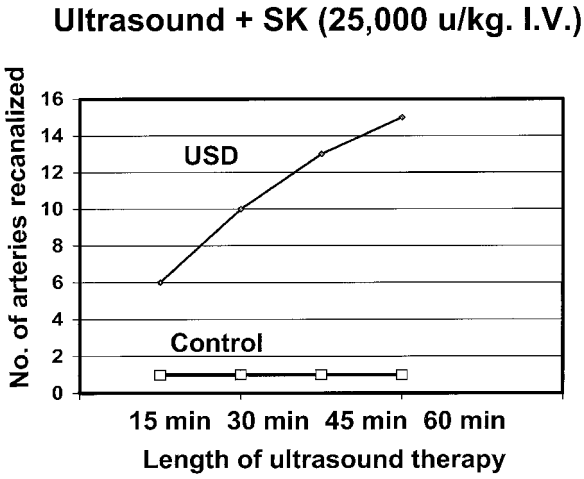

Figure 3. *Graph showing arterial patency of rabbit iliofemoral arteries that received streptokinase or streptokinase plus ultrasound. The vertical axis shows the number of rabbits and the horizontal axis shows time in minutes.*

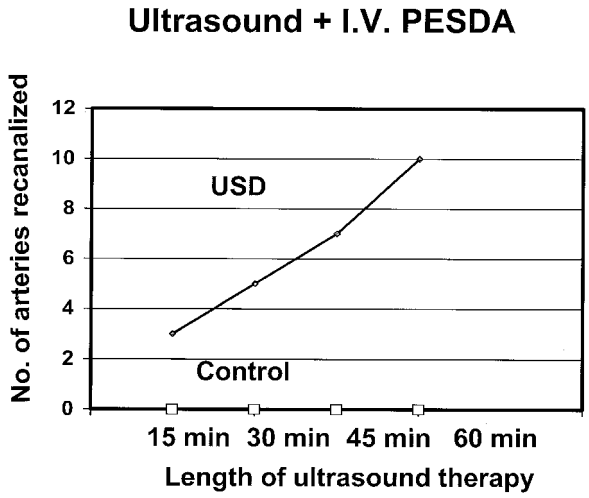

Figure 4. *Graph showing arterial patency of rabbit iliofemoral arteries that received PESDA or PESDA plus ultrasound. The vertical axis shows the number of rabbits and the horizontal axis shows time in minutes.*

(LAD) coronary artery. The guidewire protrudes 1–2 cm beyond the perfusion catheter. A 3-volt battery is attached with its positive end to the wire and the negative end to the dog's skin. During thrombus induction, the electrocardiogram (ECG) is constantly monitored. When there are ST segment changes indicative of ischemia, a 12-lead ECG is performed. If the 12-lead ECG confirms an injury pattern with ST elevation ≥ 2 mm in two contiguous leads, a selective left coronary angiogram is performed to determine if there is a thrombotic occlusion in the LAD.

Coronary Thrombolysis Protocol 1—tPA Plus Ultrasound Versus tPA Alone.[12] After documenting an LAD coronary artery thrombotic occlusion of 109 ± 62 minutes duration, 24 dogs were given an intravenous infusion of tPA (1.42 μg/kg) over 90 minutes along with heparin 1000 units intravenously. Dogs were then randomized to either the tPA infusion alone (n = 12) or combined tPA infusion and adjunctive transcutaneous low frequency (27 kHz) ultrasound (n = 12).

Coronary Thrombolysis Protocol 2—PESDA Plus Ultrasound (No Control Group). After documenting an LAD coronary artery thrombotic occlusion of 90 ± 20 minutes duration, six dogs were treated with the combination of intravenous PESDA (2 ml/15 min) and transcutaneous low frequency ultrasound (27 kHz).

Monitoring reperfusion, serial coronary angiograms were performed every 20 minutes for the first 60 minutes after starting therapy and then every 30 minutes for the next 2 hours (at 90, 120, 150, and 180 minutes). Angiograms evaluated patency and TIMI flow. If the coronary angiogram documented reperfusion of the LAD (TIMI 2–3), heparin 1000 units was given subcutaneously. In addition, 12-lead ECGs were serially monitored and obtained just prior to each coronary angiogram.

Application of Ultrasound. The ultrasound system consists of a generator/amplifier and transcutaneous transducer (Cybersonics Inc., Erie, PA, USA). The transducer manifold is coupled to a cooling system to maintain the tempera-

TABLE II

Comparison of Serum CK, LDH Levels, RBCs, and Platelet Counts

Ultrasound + SK	CK (IU/L)	LDH (IU/L)	RBCs (10^{12}/L)	Platelet (10^{11}/L)
Baseline	916 ± 399	245 ± 288	5.4 ± 0.7	2.6 ± 1.0
After electrical induction	1123 ± 499	234 ± 209	6.3 ± 0.4	2.6 ± 0.9
After ultrasound treatment	1283 ± 499	234 ± 171	5.9 ± 0.9	2.3 ± 0.7
P value	NS	NS	NS	NS

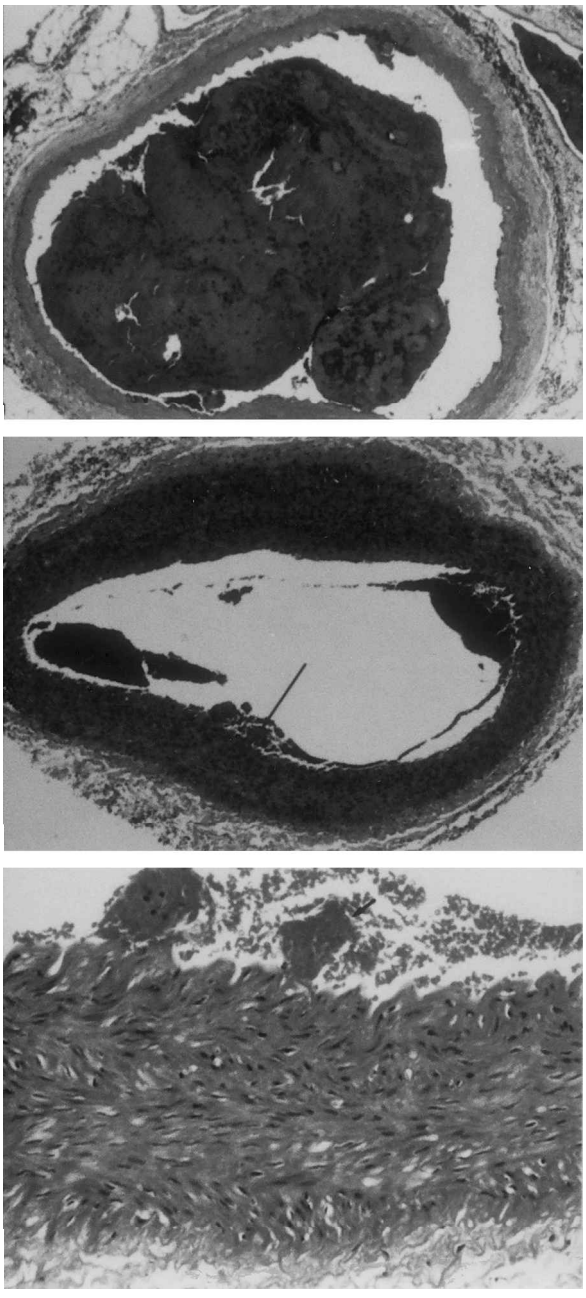

Figure 5. *Histological example of a rabbit iliofemoral artery.* **A.** *Thrombotic occlusion in an iliofemoral artery (hematoxylin and eosin stain; original magnification, x 10).* **B.** *and* **C.** *Rabbit iliofemoral artery that was angiographically patent after 30 minutes of treatment with transcutaneous ultrasound and streptokinase The patent artery has a focus residual thrombus in the lumen (arrow) without evidence of vessel damage (hematoxylin and eosin stain; original magnification,* **B.** *x 10;* **C.** *x 50).*

ture at the surface of the chest wall ≤ 98°F. For the canine studies, the 27 kHz transducer operates in a continuous mode and delivers approximately 0.9 watts per square centimeter (W/cm^2) at the surface of the transducer. The ultrasound transducer is applied to the anterior surface of the canine chest wall over the lower junction of the sternum and the rib cage. The transducer is held in a rigid ring stand and ultrasonic cooling gel is applied to the chest wall surface to facilitate transmission of ultrasound energy. If TIMI 2–3 flow occurs, 1000 units of heparin are given subcutaneously.

After TIMI 3 flow developed in the ultrasound treated group, the application of ultrasound was discontinued. Further, in an additional seven dogs, ultrasound was applied directly to the right lateral chest wall for 30 minutes to test whether ultrasound might induce gross or microscopic damage to the lung parenchyma and/or vasculature.

Measurement of Ultrasound Power Output in Vivo

To assess the transmission of transthoracic ultrasound delivery intrathoracically to the anterior and posterior surface of the heart, three additional canine studies were performed. A hydrophone (Bruel and Kjaer model 8103, Norcross, GA, USA), amplifier (Nexus model 2692), and oscilloscope (Digital Hewlett Packard Model 54600B, Andover, MA, USA) measured the intrathoracic delivery of ultrasound energy in vivo. The hydrophone was advanced through a small incision under the sternum and placed on the anterior surface of the heart or alternatively immediately beneath the posterior surface of the heart by an incision in the posterolateral chest wall. The ultrasound transducer (27 kHz, thrombo serial # M0527990190, Cybersonics, Erie, PA, USA) was placed on the anterior surface of the chest wall (lower sternum). The average peak intensity delivered by this system was 0.45 W/cm^2 below the sternum and on the anterior surface of the heart. The largest peak intensity measured on the anterior surface of the heart was 0.58 W/cm^2 and on the posterior aspect beneath the heart was 0.55 W/cm^2.

Results of Transcutaneous Ultrasound in Canine Acute Myocardial Infarction—Angiographic Findings

Canine Protocol 1 (tPA Plus Ultrasound Versus tPA Alone).[12] Figure 6 shows the angiogram and the ECGs taken in the same time

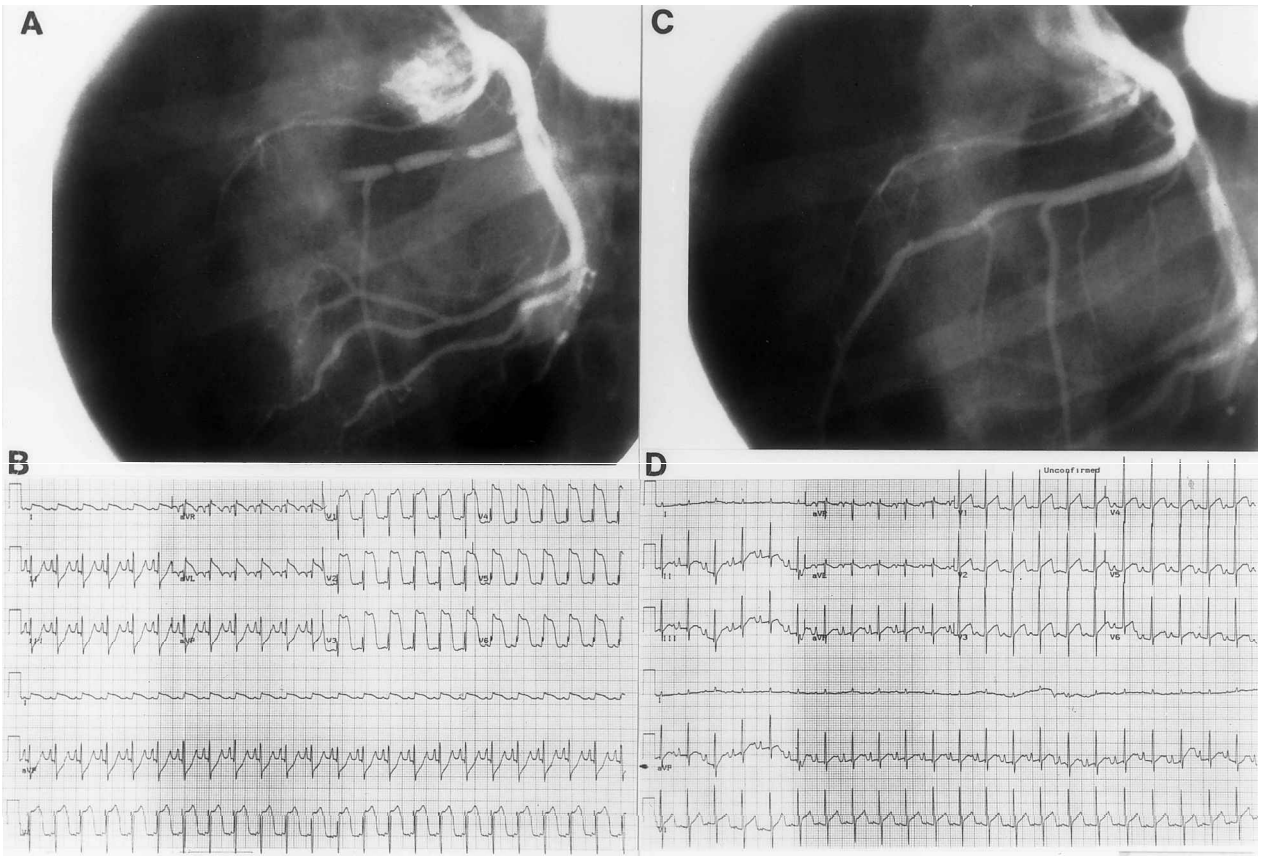

Figure 6. *LAD thrombotic occlusion treated with the combination of tPA plus ultrasound and the corresponding 12-lead ECG.* **A.** *Baseline left coronary angiogram and ECG.* **B.** *Angiogram of the thrombotically occluded LAD and acute ECG injury pattern.* **C.** *Angiographic patency and resolution of the ECG ST segment elevation after 20 minutes of treatment.*

period of a thrombotic LAD occlusion which was subsequently reperfused at 20 minutes using the combination of intravenous tPA (1.4 μg/min) and transcutaneous ultrasound. Mean data for the tPA alone group versus the tPA plus ultrasound group at 90 minutes of therapy and after a subsequent 90 minute observation period is shown in Figure 7. Note the mean TIMI flow is significantly better ($P < 0.01$) in the tPA plus ultrasound group at 90 minutes (2.42 versus 0.92 in the tPA alone group). At 180 minutes, the TIMI flow in the tPA plus ultrasound group rose to 2.58 as compared with the tPA alone group, which decreased to 0.75 due to spontaneous coronary reocclusion during the 90 minute observation period.

As shown in Table III, at 20 minutes, eight dogs receiving tPA plus ultrasound had TIMI 3 flow, two had TIMI 2 flow, one had TIMI 1 flow, and one had TIMI 0 flow. Four dogs in the tPA alone group had TIMI 3 flow, one had TIMI 2 flow, and the other seven had persistent occlusion (TIMI 0 flow). By 90 minutes, the group receiving tPA plus ultrasound had a 3-fold greater frequency of TIMI 3 flow than those receiving tPA alone.[11] The incidence of TIMI 2–3 flow at 180 minutes was 3/12 (25%) with tPA alone as compared with 11/12 (92%) using the combination of tPA plus ultrasound. The aPTT and prothrombin time (PT) levels were measured and were the same in both groups. Nonetheless, coronary arterial reocclusion occurred in 2/5 (40%) of the tPA alone group (one dog with TIMI 3 flow and one dog with TIMI 2 flow), while there were no reocclusions (0/11) in the tPA plus ultrasound group.

Canine Protocol 2 (PESDA Plus Ultrasound). Of six dogs treated, three reperfused within 2 hours. One dog reperfused with TIMI 3 flow at 30 minutes, another dog had TIMI 3 flow at 120 minutes, and another had TIMI 2 flow at 120 minutes. The other three dogs had persistent thrombotic LAD occlusion (TIMI 0 flow) at 120 minutes.

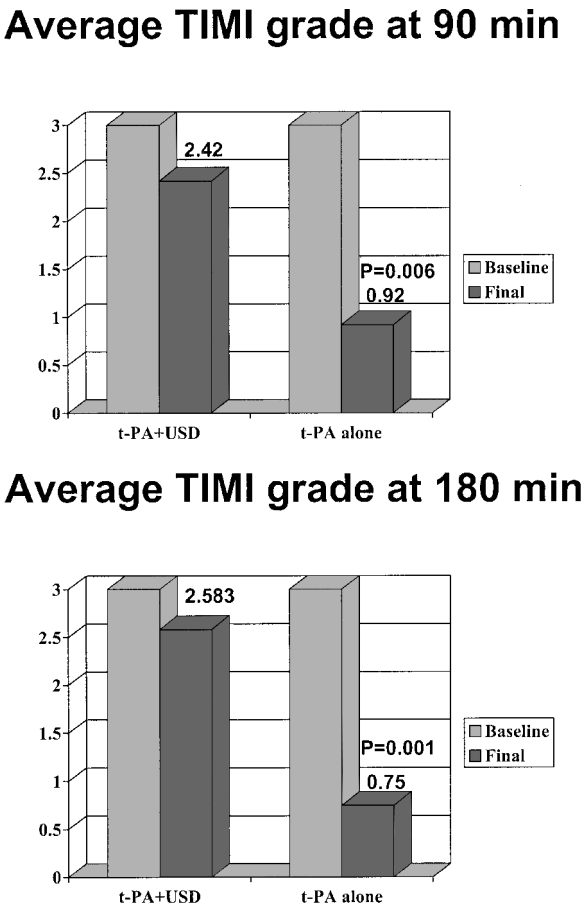

Figure 7. *Bar graphs show the grade of TIMI flow at 90 and 180 minutes after initiating intravenous tPA as compared with intravenous tPA plus transthoracic ultrasound (USD).*

Pathologic Studies. Figure 8 Shows a patent LAD treated with tPA and ultrasound. The arrow indicates a site of intimal arterial damage due to electric induction of the thrombus. Eleven of 12 patients were treated with tPA plus ultrasound, and 2 of 6 treated with PESDA plus ultrasound had minimal (< 25% of the vessel circumference) thrombus or no thrombus detected. There was no evidence of ultrasound-mediated injury, vacuolization, or blast injury in the skin, soft tissue, myocardium, and coronary arteries. In the tPA alone group, there was one case of distal coronary arterial embolization. However, distal embolization was not detected in any cases from the group receiving tPA and adjunctive ultrasound. Consistent with the angiographic findings, nine of 12 arteries in the tPA alone group were thrombotically occluded. In addition, there was no gross or histologic evidence of ultrasound-induced damage to the lung parenchyma or vasculature in any of the 12 dogs treated with ultrasound plus tPA applied to the anterior chest wall, or in the seven dogs who received ultrasound applied for 30 minutes directly over the right hemithorax, or in the six dogs receiving PESDA who had up to 120 minutes of ultrasound applied over the left hemithorax.

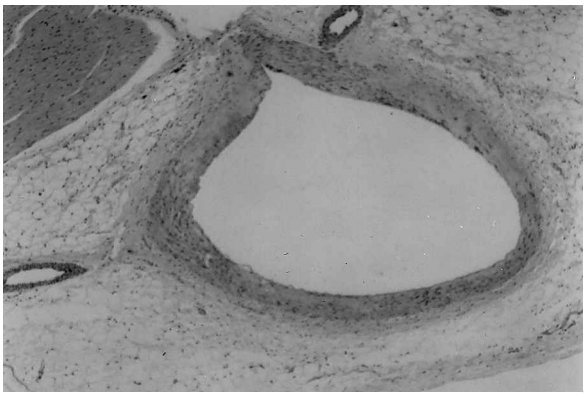

Figure 8. *A patent LAD after tPA and ultrasound treatment.*

Discussion

Peripheral Arterial Clot Dissolution

Ultrasound in Combination with Thrombolytic Drugs. In our studies of rabbit iliofemoral thrombotic occlusion, low frequency ultra-

TABLE III

Coronary Angiographic Results

	At 20 Minutes		At 90 Minutes		At 180 Minutes	
	tPA Alone	tPA + USD	tPA Alone	tPA + USD	tPA Alone	tPA + USD
TIMI 3	4	8	3	8	3	9
TIMI 2	1	2	1	2	0	2
TIMI 1	0	1	0	1	0	0

sound (20–37 kHz) is highly effective in augmenting clot dissolution in combination with thrombolytic drugs. The study in protocol 1 was the first angiographic/histologic study in which transcutaneous ultrasound was used in an intact animal model with a thrombotic arterial occlusion.[7] The rate of patency in our three studies with streptokinase plus ultrasound ranged from 56%–100% as compared with 6% (3/47) in control vessels.[7–9] Ultrasound alone, like streptokinase alone, was ineffective for lysis of the rabbit iliofemoral thromboses. Thus, for effective thrombolysis in this model, synergy between ultrasound and the drug is requisite. The improvement in the thrombolysis rate in our laboratory between the studies was initially 56% and has increased recently to 100% of rabbits' iliofemoral arteries. This increase in the rate of thrombolysis reflects the development and technical improvement in ultrasound transducer design and performance. The earlier studies were with early prototype devices and the latter units were specifically designed for peripheral arterial application.

Peripheral Arterial Studies by Others. Using a different rabbit model of femoral arterial thrombosis and a considerably higher frequency of ultrasound (1 MHz), Riggs et al. found a several-fold increase in the thrombolysis rate when combining ultrasound and streptokinase as compared with streptokinase alone (9/17 [53%] vs 2/15 [13%], P = 0.025).[13] Using a canine femoral arterial thrombosis model with a thrombolytic agent and 20 kHz transcutaneous ultrasound, Hamano et al. showed significantly more rapid lysis when using the combination of ultrasound and a thrombolytic agent than a lytic agent alone.[14] Similarly, Kudo showed more brisk lysis of surgically exposed thrombotic canine femoral arteries treated with the combination of ultrasound and tPA as compared with tPA alone.[15]

Coronary Arterial Clot Dissolution. These canine studies are the first in vivo demonstration that noninvasive ultrasound can be used to facilitate coronary thrombolysis.[12] As shown in Figure 7 and Table III, at 90 minutes the mean TIMI grade flow for the tPA alone group was 0.92 ± 1.4 versus 2.42 ± 0.99 in the tPA plus adjunctive transthoracic low frequency (27 kHz) ultrasound group. Twice as many dogs receiving adjunctive transthoracic ultrasound had TIMI 3 flow at 20 minutes as compared with those receiving tPA (and heparin bolus) alone (eight vs four). On follow-up angiogram 180 minutes after completion of the tPA infusion, there was a significant 3-fold greater incidence of TIMI 3 flow in the ultrasound group (nine vs three, P = 0.039). Two of the five arteries patent in the tPA alone group reoccluded as compared with no reocclusion (zero of 11) in the ultrasound group (P = 0.27). The low incidence of reocclusion in the ultrasound-treated group might reflect more complete thrombolysis, better coronary blood flow, and coronary vasodilation, and might be associated with ultrasound exposure[16–18] and/or the absence of significant downstream embolization in the ultrasound treatment group. The aPTT and PT were the same in both groups, and thus did not account for the differences in patency rate, speed of thrombolysis, or arterial reocclusion in the two groups.

Gross and histopathologic studies confirm the angiographic patency of vessels after treatment in each group. There is ≤ 25% CSA residual thrombus in those cases with angiographic TIMI 2–3 flow. Distal embolization from the proximal portion of the LAD to the distal one-third of the artery as well as distal embolization to smaller arterial branches was only detected in one vessel of a dog that received tPA alone.

Data from this and previous studies using similar transcutaneous low frequency ultrasound devices[5, 9, 12] suggest that this method is safe and without acute adverse effects. We found no gross or histopathologic evidence of ultrasound or thermal damage to the treatment area, namely to the exposed skin, soft tissue, myocardium, coronary blood vessels, and cardiac conduction system, or to the pulmonary parenchyma or vasculature. The absence of damage is consistent with the use of peak intensity levels being 0.58 W/cm^2 on the anterior surface of the heart. This peak intensity of ultrasound used in this study is well below the value described by Suchkova et al.[19] as possibly having thermal effects.

Francis et al. and Suchkova et al. showed that low frequency ultrasound accelerates enzymatic thrombolysis at intensities similar to those used in our study (≥ 0.25 W/cm^2).[19,20] Moreover, low frequency ultrasound has excellent tissue penetration for effective clot lysis and can be accomplished with minimal heating.[5,8,9,12] Ultrasound enhancement of tPA fibrinolysis occurs with minimal mechanical effect on the clot and occurs in the absence of heating (a nonthermal effect).[3,12,19] The enhancement of clot lysis appears to be related to an increase in drug penetration into the clot as

well as an increase in the enzymatic reaction of the lytic drug at the site of the clot.[20–23] This effect is not fibrinolytic-specific and is shown to occur with tPA, streptokinase, and urokinase. The multiple mechanisms for the augmentation of fibrinolysis are primarily elucidated by Francis et al.[19–23] A primary effect of ultrasound, which results in augmentation of fibrinolysis, is an increase in transport of the fibrinolytic enzyme into the clot. Ultrasound exposure increases both tPA uptake by clots as well as the depth of penetration of the drug into the clot. Siddiqi et al. showed that ultrasound enhances fluid permeation through fibrin gels.[22] Using scanning electron microscopy, Braaten et al. demonstrated that ultrasound reversibly disaggregates fibrin fibers, which accounts for the increase in permeability (decrease in flow resistance) of fibrin gels exposed to ultrasound.[23] This effect is thought to promote an increase in fibrin binding sites for fibrinolytic agents and further facilitate clot dissolution.

Limitations

Several limitations and unresolved issues still need to be addressed in future studies of noninvasive transcutaneous ultrasound for facilitation of peripheral and coronary thrombolysis. To date, studies have been done with early generation prototype therapeutic ultrasound devices. Further studies should evaluate the newer thrombolytic agents as well as antiplatelet drugs.

Conclusions

Studies from the laboratories of others as well as ours demonstrate that a nonpharmacologic, noninvasive approach is feasible to facilitate peripheral and coronary thrombolysis. We found that the combination of transcutaneous, low frequency ultrasound significantly augments the effectiveness of thrombolytic drugs. The theoretical advantages of this approach include:

1. improved efficacy of the thrombolytic drug,
2. enhancement of thrombolytic effect is localized to the ultrasound treatment area,
3. no augmentation of systemic bleeding risk by the addition of ultrasound, and
4. no additional adverse interactions, as may occur with adjunctive pharmacotherapy for thrombolysis.

Transcutaneous low frequency ultrasound appears to be an ideal adjunctive method to improve thrombolytic therapy by increasing the rapidity and magnitude of the restoration of blood flow without adversely affecting the risk of bleeding.

Acknowledgement: The authors gratefully acknowledge the inspiration and vision of Dr. William Ganz.

References

1. Luo H, Nishioka T, Berglund H, et al: Effect of external ultrasound frequency on thrombus disruption in vitro. *J Thrombosis Thrombolysis* 1996;3:63-66.
2. Luo H, Steffen W, Cercek B, et al: Enhancement of thrombolysis by external ultrasound. *Am Heart J* 1993;125:1564-1569.
3. Luo H, Steffen W, Cercek B, et al:. External ultrasound enhances chemical thrombolysis (Abstract). *Circulation* 1993;88:I-264.
4. Nishioka T, Luo H, Fishbein MC, et al: Dissolution of thrombotic arterial occlusion by high intensity, low frequency ultrasound and dodecafluoropentane emulsion: In vitro and in vivo study. *J Am Coll Cardiol* 1997;30:561-568.
5. Birnbaum Y, Luo H, Nagai T, et al: Recanalization of thrombosed iliofemoral arteries by transcutaneous ultrasound combined with intravenous infusion of microbubbles. *Circulation* 1998;97:130-134.
6. Birnbaum Y, Iakobishvili Z, Porter A, et al: Microparticle-containing oncotic solutions augment in vitro clot disruption by ultrasound. *Thromb Res* 2000;98: 549-557.
7. Luo H, Nishioka T, Fishbein MC, et al: Transcutaneous ultrasound augments lysis of arterial thrombi in vivo. *Circulation* 1996;94:775-778.
8. Luo H, Fishbein MC, Bar-Cohen Y, et al: Cooling system permits effective transcutaneous ultrasound clot lysis in vivo without skin damage. *J Thrombosis Thrombolysis* 1998;6:125-131.
9. Luo H, Birnbaum Y, Fishbein MC, et al: Enhancement of thrombolysis in vivo without skin and soft tissue damage by transcutaneous ultrasound. *Thromb Res* 1998;89:171-177.
10. Salazar AE. Experimental myocardial infarction-induction of coronary thrombosis in the intact closed-chest dog. *Circ Res* 1961;9:1351-1356.
11. Steffen W, Fishbein MC, Luo H, et al: High intensity, low frequency catheter-delivered ultrasound dissolution of occlusive coronary artery thrombi: An in vitro and in vivo study. *J Am Coll Cardiol* 1994;24:1571-1579.
12. Siegel RJ, Atar S, Fishbein FC, et al: Noninvasive transthoracic low frequency ultrasound augments thrombolysis in a canine modal of acute myocardial infarction. *Circulation* 2000;101:2026-2029.
13. Riggs PN, Francis CW, Bartos SR, et al: Ultrasound enhancement of rabbit femoral artery thrombolysis. *Cardiovasc Surg* 1997;5:201-207.
14. Hamano K, Kudo S, Hara M, et al: A new noninvasive thrombolysis enhanced by transcutaneous ultrasonic irradiation. *Eur Heart J* 1991;12:135.
15. Kudo S. Thrombolysis with ultrasound effect. *Tokyo Jikeikai Med J* 1989;104:1005-1012.
16. Fischell TA, Abbas M, Grant GW, et al: Ultrasound

energy: Effect on vascular function and integrity. *Circulation* 1991;84:1783-1795.

17. Siegel, RJ, Gaines P, Procter A, et al: Clinical demonstration of intraarterial ultrasound energy inducing arterial vasodilation. *J Am Coll Cardiol* 1992;20: 732-735.
18. Steffen W, Cumberland DC, Gaines P, et al: Catheter-delivered high intensity, low frequency ultrasound induces vasodilation in vivo. *Eur Heart J* 1994;15: 369-376.
19. Suchkova V, Siddiqi FN, Carstensen EL, et al: Enhancement of fibrinolysis with 40 kHz ultrasound. *Circulation* 1998;98:1030-1035.
20. Francis CW,Önundarson PT, Carstensen EL, et al: Enhancement of fibrinolysis in vitro by ultrasound. *J Clin Invest* 1992;90:2063-2068.
21. Blinc A, Francis CW. Transport processes in fibrinolysis and fibrinolytic therapy. *Thromb Haemost* 1996; 76:481-491.
22. Siddiqi FN, Blinc A, Braaten J, et al: Ultrasound increases flow through fibrin gels. *Thromb Haemost* 1995;73:495-498.
23. Braaten J, Goss RA, Francis CW. Ultrasound reversibly disaggregates fibrin fibers. *Thromb Haemost* 1997;78:1063-1068.